

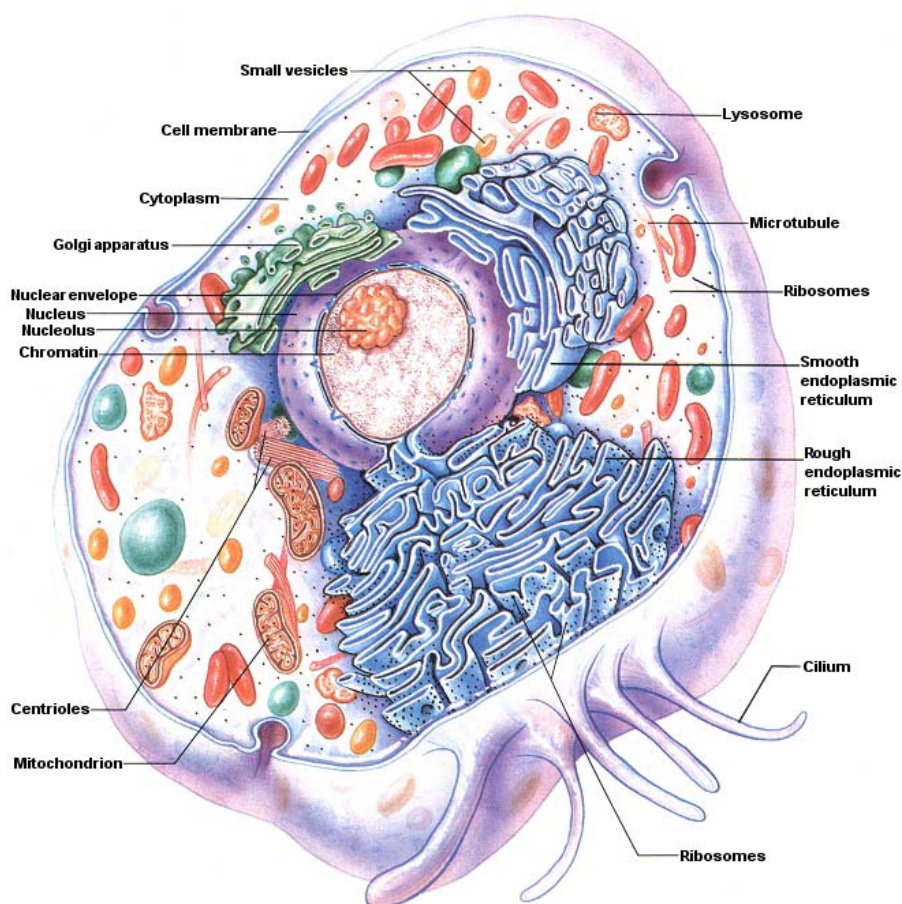
The organism works as a whole with each individual cell requiring food and oxygen and having a need to be rid of waste products. Each cell is sensitive to any change in its surroundings, and malfunction of any of its parts may upset the balance of the whole. The organism is dependant upon proper collective function of its individual cells, and the individual cells are dependant upon the organism providing servicing of cellular needs, nutrition and the correct environment in which the cells can prosper.

## CELLS AND TISSUES

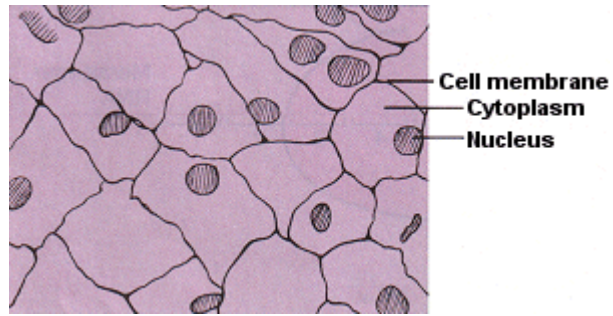
If almost any structure from a plant or animal is examined microscopically it will be seen to consist of more or less distinct units – cells – which, although too small to be seen individually, in large numbers make up the structure or organ.

All cells have a cell membrane, a thin boundary skin enclosing the cytoplasm.

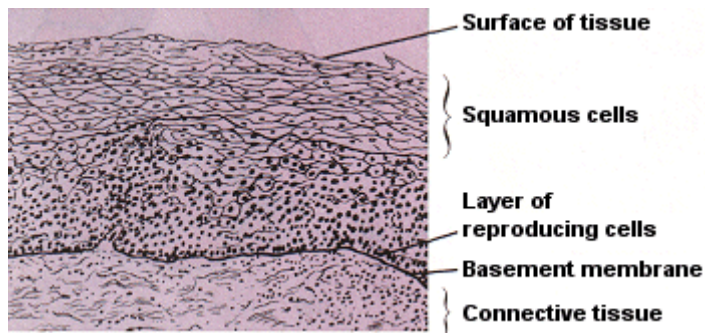
Most cells have a nucleus.




*A Typical Animal Cell*



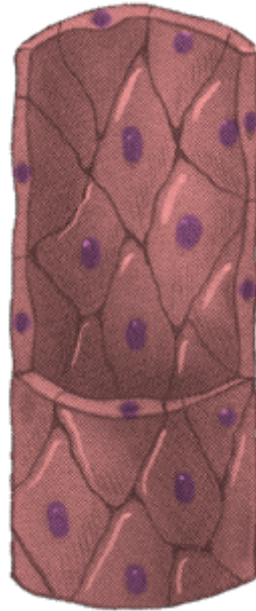*SQUAMOUS EPITHELIUM*  
*in a single layer (surface view)*



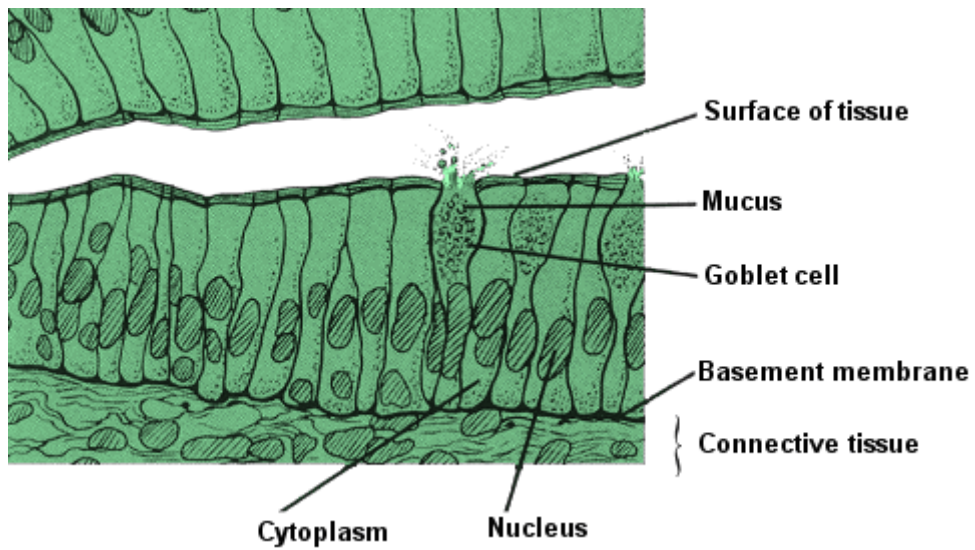
*SQUAMOUS EPITHELIUM*  
*in several layers (side view)*



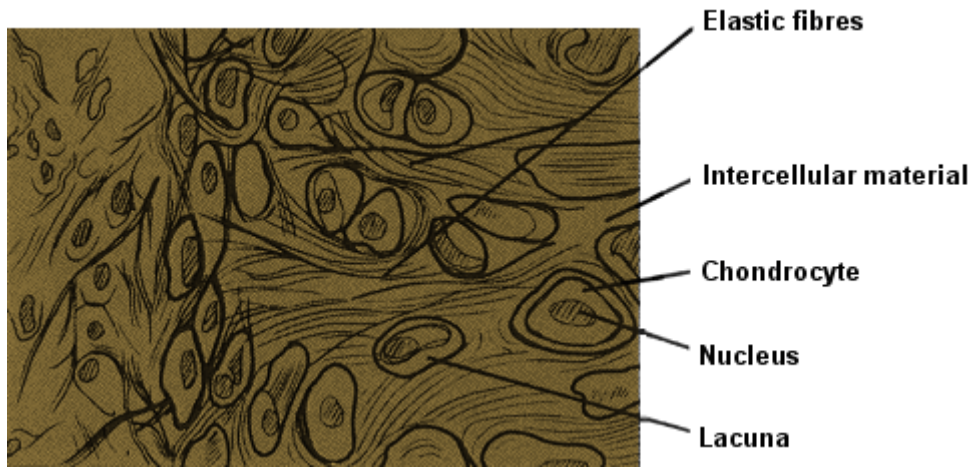
*WHITE FIBROUS TISSUE*



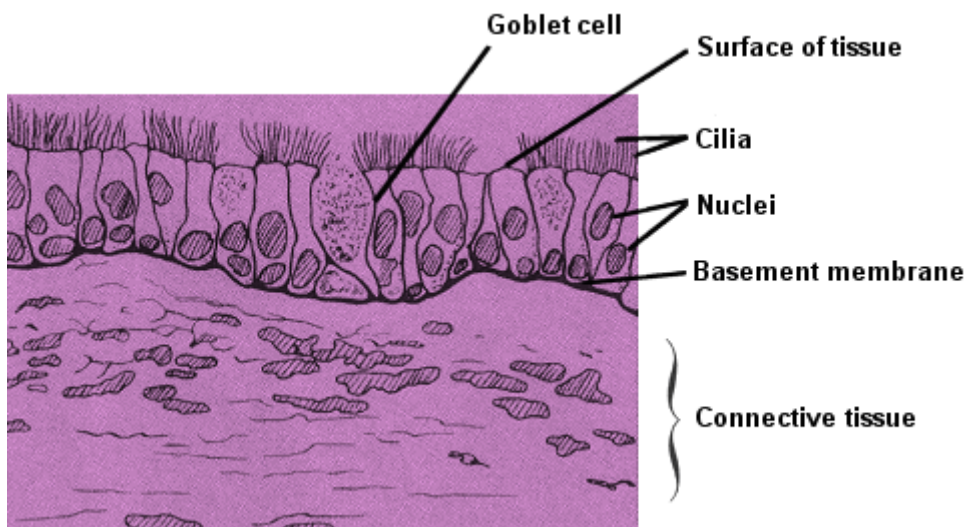
*SQUAMOUS EPITHELIUM*  
*forms the walls of capillaries*



*COLUMNAR EPITHELIUM*



*YELLOW ELASTIC TISSUE*



*CILIATED COLUMNAR EPITHELIUM*

## CELLULAR TISSUES

### TISSUES

*A tissue such as bone, nerve or muscle is made up of many hundreds of cells. These cells are of just a few types. The cells of each type have similar structures and functions.*

There are four major types of tissues:

**1. Epithelial** Epithelial tissue is arranged in single or multi-layered sheets and covers the internal and external surfaces of the body-skin and mucosa

**2. Connective** Connective tissue is the major supporting tissue of the body, and includes skeletal tissue. All connective tissue has fibres present in the form of yellow fibres (elastin), or white fibres (collagen)

White fibres are tough and non-elastic and are found in white fibrous connective tissue. They are present in tendons, cartilage, bone and the sclerotic layer of the eyeball

Yellow fibres are found in yellow elastic tissues such as ligaments, lungs and associated air passages

Cartilage is a connective tissue with cartilage cells embedded in a matrix of chondrin. Cartilage may have white or yellow fibres

Bone is a calcified connective tissue consisting of a matrix of 30% organic material and 70% of bone salts – principally calcium and magnesium salts

Blood is regarded as a connective tissue

**3. Muscle** There are three types of muscle tissue:

- i. Voluntary, skeletal or striated – attached to bone and under conscious control. These tissues provide powerful and rapid contraction
- ii. Involuntary or smooth – found in the walls of blood vessels and lining the walls of hollow organs such as the gut and bladder. These muscles contract slowly but powerfully and can work for long periods without rest, for instance, to churn food and force it along the intestine
- iii. Cardiac – found only in the heart and producing rapid, rhythmical contractions throughout life.

**4. Nervous** Nervous tissue consists of neurons, the functional units of the nervous system.